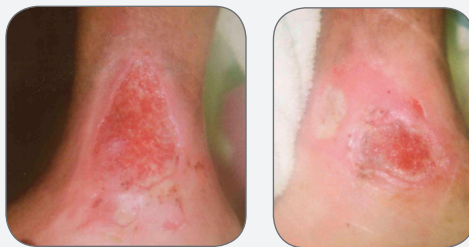

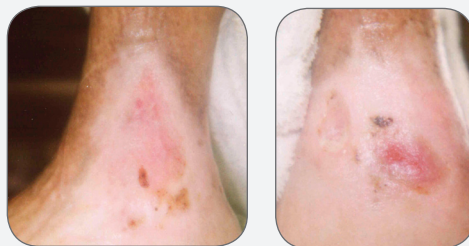


## CASE STUDY

# Three Malleolus Wounds of Two Years' Duration Closed in Four Weeks Using PolyMem Silver®



INITIAL WOUND PRESENTATION



CLOSED AFTER FOUR WEEKS

## CASE STUDY

# Three Malleolus Wounds of Two Years' Duration Closed in Four Weeks Using PolyMem Silver

Judy Caras RN, CWOCN, Mercy Hospital Bakersfield, 2215 Truxtun Avenue, Bakersfield, CA 93301

### PROBLEM

A 65-year-old female with a history of venous insufficiency presented with wounds of the left lateral and medial malleolus. The patient's history included chronic arthritis, hypertension, hypothyroidism, immobility and left malleolus wounds present for the last 2 years. The patient was hospitalized with a gastrointestinal bleed and severe anemia. A past wound culture showed MRSA in the wounds. Additionally, the patient had possible pseudomonas colonization. A Wound Ostomy Continence Nurse was consulted for wound care. The patient lives in a desert environment which can interfere with optimum moist wound healing conditions.

### DESCRIPTION OF PAST MANAGEMENT

Past wound treatment included conservative debridement, daily wet-to-dry dressings or weekly compression therapy after debridement. All previous treatments were found unsuccessful. The patient had pain with dressing changes.

### CURRENT CLINICAL APPROACH

The new plan of treatment included applying high lanolin content skin protectant to the leg, debride as needed, cover with PolyMem Silver dressing and apply 4-layer bandage system compression therapy. The dressing and compression therapy were changed once per week. The PolyMem Silver dressing selection was based on the wound culture results and the fact that the dressings can be used up to 7 days. PolyMem Silver dressings have been tested and found to be effective against: Staphylococcus Aureus both MRSA and Non-MRSA, Enterococcus Faecalis (VRE), Klebsiella Pneumoniae, Pseudomonas Aeruginosa and Candida Albicans.

### PATIENT OUTCOME

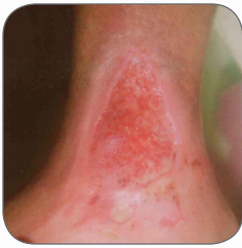These chronic non-healing wounds healed in 4 weeks after initiation of management with PolyMem Silver dressings. Only 5 dressing changes were required in order to achieve wound closure. The patient did not experience any maceration of the wound or periwound area with this management approach.

The wound bed did not need to be cleansed during dressing changes after the PolyMem Silver dressings were initiated. The clinician attributes this to the continuous cleansing that the PolyMem Silver dressing provides during use.

The wound debrided and cleaned up faster and closed sooner than the clinician expected.

The PolyMem Silver dressing is non-adherent which made dressing changes very comfortable for the patient. The patient did not have pain with dressing changes when using the PolyMem Silver dressing.

Lateral Aspect of L Malleolus



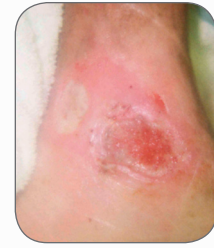**MAY 20**

Left lateral malleolus wound 6 cm x 4.5 cm depth 0.5 cm, granulation tissue present.

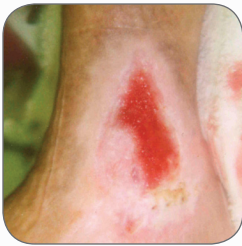Left medial malleolus wound 4.5 cm x 4 cm depth 0.4 cm.  
Left medial posterior malleolus wound 2 cm x 2 cm depth 0.5 cm, 100% yellow slough tissue.

Erythema present to surrounding skin. PolyMem Silver dressings initiated with compression therapy.

Medial Aspect of L Malleolus



Lateral Aspect of L Malleolus

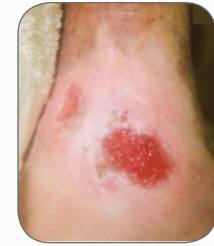

**JUNE 2**

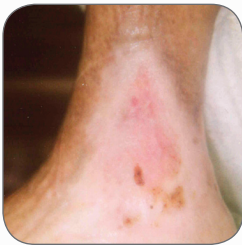Left lateral malleolus wound 5 cm x 3 cm, resurfacing present, no odor noted. Scant amount sanguinous drainage and periwound softening callous.

Left medial malleolus wound 3.5 cm x 2.5 cm.  
Left medial posterior malleolus wound 2 cm x 1.5 cm, resurfacing noted.  
100% wound granulation.

Medial Aspect of L Malleolus



Lateral Aspect of L Malleolus

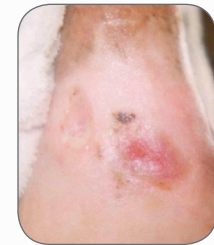

**JUNE 17**

Left lateral and medial malleolus resurfaced.

Wounds closed.

Medial Aspect of L Malleolus



**CONCLUSION**

PolyMem Silver dressings are an excellent choice to use under compression. PolyMem Silver dressings maintained an ideal moist wound healing environment even in these desert conditions. PolyMem Silver dressings offer quicker wound resolution times than traditional dressings and have been found to help heal wounds that had previously been unsuccessfully treated. PolyMem Silver dressings deliver 4 aspects of wound care in 1 formulation (cleanses, fills, absorbs, moistens) which can be used throughout the wound-healing continuum. The dressing eliminates multiple wound products and has been found to be cost-effective. This type of dressing can be used successfully with or without compression therapy.

**OBJECTIVES**

1. Discuss problematic issues related to malleolus wounds.
2. Identify PolyMem Silver dressings to help reduce bacterial burden and enhance wound healing throughout the wound healing continuum.
3. Discuss using PolyMem Silver dressings with compression therapy for treatment of venous insufficiency.
4. Identify PolyMem Silver dressings to be a cost-effective choice for wound management.

This case study was unsponsored. Ferris Mfg. Corp. contributed to the poster presentation.



**Ferris Mfg. Corp.**

5133 Northeast Parkway | Fort Worth, TX 76106 USA

Toll Free USA: 1.800.POLYMEM (765.9636) | International: +1 817.900.1301

Web site: [www.PolyMem.com](http://www.PolyMem.com)

**BIBLIOGRAPHY:**

1. Cutting KF, White RJ. Criteria for identifying wound infection-revisited. *Ostomy Wound Management*. 2005;51(1):28-34.

2. Ovington LG. Hanging wet to dry dressings out to dry. *Home Healthcare Nursing* 2001; 19(8):477-483.

3. Ovington LG. The truth about silver. *Ostomy Wound Management*. 2004 Sept;50(9A Supplement):1S-10S.

4. Polymem Silver Antimicrobial Testing Summary MKL-177.

5. Lansdown ABGM Silver I: It's antimicrobial properties and action. *Journal Wound Care*. April 2002;11(4): 125-130.

**ORIGINAL POSTER PRESENTED AT\*:**

19th Annual Symposium on Advances in Skin & Wound Care (SAWC). Poster #82. April 30 – May 3, 2006. San Antonio, TX USA

38th Annual WOCN Society Conference. Poster #144/Abstract #1812. June 24 – 28, 2006. Minneapolis, MN USA

21st Annual Clinical Symposium on Advances in Skin & Wound Care. Poster #69. September 28 - October 1, 2006. Orlando, FL USA

10th Annual Wound Care Congress. Poster #3. November 12 – 14, 2006. Colorado Springs, CO USA

\* This version has been modified from the original; it reflects PolyMem branding.

PolyMem, PolyMem Silver, PolyMem Wic, Wic, PolyMem Wic Silver, PolyMem Wic Silver Rope, PolyMem Max, Max, PolyMem Max Silver, Shapes, Shapes by PolyMem, The Shape of Healing, The Pink Dressing, SportsWrap, SportsWrapST, More Healing • Less Pain, interlocking circles design, PolyMem For Sports, Not too Loose...Not too Tight...Just Right!, Ferris and FMC Ferris and design are marks owned by or licensed to Ferris. The marks may be registered or pending in the US Patent and Trademark Office and in other countries. Other marks are the property of their respective owners.

© 2013 Ferris Mfg. Corp.

MKL-282,REV-4,0613