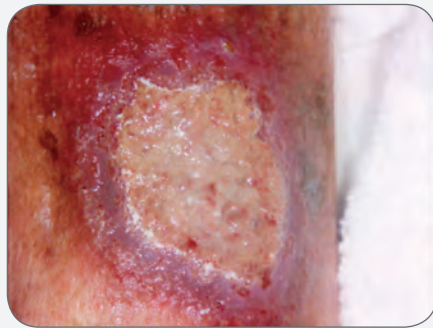


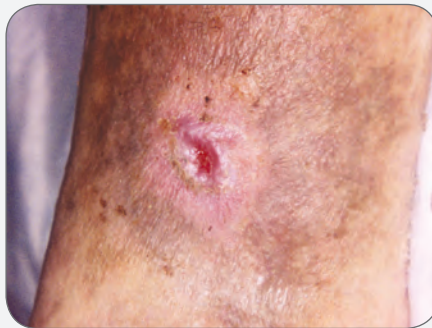

CASE STUDY

Chronic Venous Leg Ulcer Closed in Only Seven Dressing Changes Using PolyMem Silver® Dressings



PRE-TREATMENT



SIXTH WEEKLY DRESSING CHANGE

CASE STUDY

Chronic Venous Leg Ulcer Closed in Only Seven Dressing Changes Using PolyMem Silver Dressings

Katherine Thurs RN, MSN, NP-C, WCS, Rice Medical Center, 824 Illinois Ave, Stevens Point, WI 54481

CLINICAL PROBLEM

A 28-year-old male presented on September 12th at the outpatient wound clinic with a chronic, non-healing right lower leg ulcer. The wound was present for 9 months prior to attending the clinic. The patient had a history of untreated Crohn's disease, venous hypertension and tobacco addiction with a two pack/day history. The patient continued employment as a bartender with long periods of standing because of limited finances. He complained of continuous right leg ulcer pain. Suspected pyoderma gangrenosum was ruled out. Previous wound care treatments included sharp and enzymatic debridement, wet-to-dry dressings, topical antimicrobial treatments, and oral antibiotic therapy based upon a wound culture, all with little improvement. The right lower leg ulcer measured 4.5 cm x 3.7 cm x 0.3 cm and had an unhealthy yellow wound base.

CURRENT APPROACH

New wound care management was initiated on October 4th: a PolyMem Silver dressing was applied with a compression wrap at 30 - 40 mm Hg. The dressing and wrap remained in place for 7 days without maceration. The dressing and wrap were changed weekly until wound closure. PolyMem Silver was able to deliver the wound care functions needed in 1 easy-to-use dressing. Frequently this clinician will switch from Silver to non-silver PolyMem dressings when the wound bed appears pink and granulating. PolyMem Silver dressings were utilized to complete wound closure in this case because of the patient's history of infection.

PATIENT OUTCOME

A total of only seven 4 x 4 PolyMem Silver dressings were utilized for this patient's care. PolyMem Silver saved time because no cleansing of the wound bed or protecting the periwound skin area was needed at dressing changes. Also, less time was spent removing the dressings because there was no adherence to the intact skin or wound bed. The need for wound pain medications was completely eliminated.

The wound appeared much cleaner and pinker with the use of PolyMem Silver dressings. There was very little fibrin build-up with the use of this dressing compared to the antibacterial cream, moist dressings or even the topical debriding ointment.

When other dressings were used, the wound bed was irrigated with normal saline or sterile water. No cleansing of the wound at dressing changes was done when PolyMem Silver dressings were used. The intact lower leg skin was washed with mild soap and moisturized under the compression wrap to maintain healthy skin integrity. Care was taken to not wash, irrigate or disrupt the wound bed.

The patient's pain decreased with the use of PolyMem Silver dressing, and compression therapy was tolerated. The right lower leg ulcer healed within 6 weeks of the initiation of PolyMem Silver dressings; this represents a dramatic improvement in healing time.

Pain was significantly reduced for this patient with the use of PolyMem Silver dressings. There was a decrease in the frequency of dressing changes, decrease in bacterial load, and decrease in fibrin build up which meant that painful debridements were not needed. Additionally, PolyMem Silver dressings are very comfortable because they absorb exudate and do not adhere to the wound bed or to intact skin.

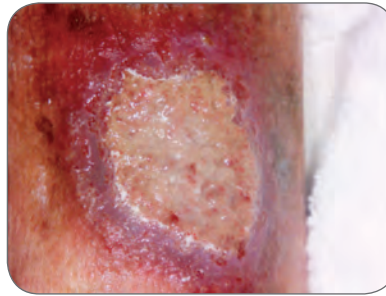
CONCLUSION

PolyMem Silver dressings were used in combination with compression therapy for successful management/healing of this venous hypertension wound. PolyMem Silver dressings' reduction in the patient's wound pain allowed the patient to tolerate clinically therapeutic compression. PolyMem Silver was effective for managing pain, managing exudate, decreasing bacterial count, providing moist wound healing and eliminating the need to debride the wound bed, while improving healing time. The patient exhibited no signs of maceration to the wound or periwound area, even though the dressings were only changed weekly. Also, PolyMem Silver dressings were ideal because of their relative low cost combined with their ease of use and the reduction in number of dressing changes required to reach complete closure. In short, PolyMem Silver dressings were both cost effective and time efficient.

OBJECTIVES

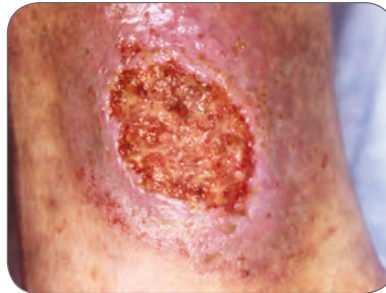
1. Discuss possible complications interfering with healing in chronic venous hypertension ulcers.
2. Discuss the combination of PolyMem Silver dressings and compression therapy for healing venous hypertension ulcers.
3. Identify PolyMem dressings to be cost effective when managing wound healing.

This case study was unsponsored. Ferris Mfg. Corp. contributed to the poster presentation.



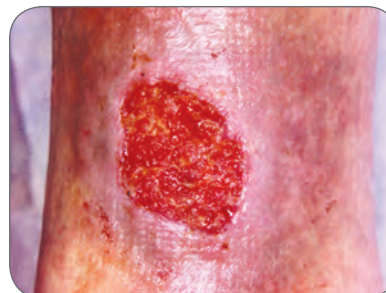
SEPTEMBER 27:

4.5 cm x 3.7 cm x 0.3 cm
100% yellow slough tissue visible in the wound bed.
Erythemic periwound skin.
Hemosiderin deposits present.



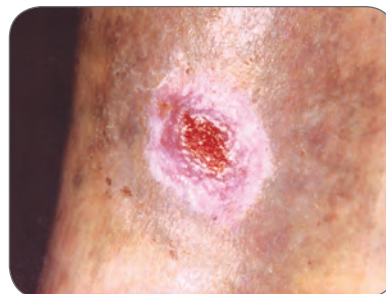
OCTOBER 4:

PolyMem Silver dressing initiated with compression therapy.



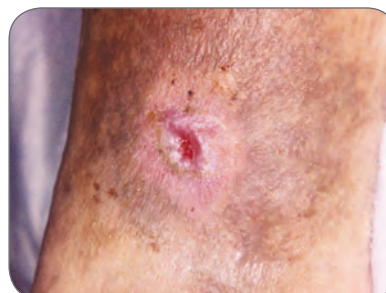
OCTOBER 11:

2.8 cm x 2.2 cm
100% granulation tissue present in the wound bed.
Erythema of periwound area decreased.



NOVEMBER 1:

0.8 cm x 0.7 cm
Wound healing well.
Re-epithialization occurring.



NOVEMBER 8:

0.4 cm x 0.1 cm
Wound continuing to heal.
PolyMem Silver dressing was utilized until November 15 when the wound was closed.



Ferris Mfg. Corp.

5133 Northeast Parkway | Fort Worth, TX 76106 USA

Toll Free USA: 1.800.POLYMEM (765.9636) | International: +1 630.887.9797

Web site: www.PolyMem.com

BIBLIOGRAPHY:

1. Cutting KF, White RJ. Criteria for identifying wound infection-revisited. *Ostomy Wound Management*. 2005;51(1):28-34.

2. Ovington LG. The truth about silver. *Ostomy Wound Management*. 2004 Sept;50(9A Supplement):1S-10S.

3. Hess CT. *Wound Care Clinical Guide*. 5th edition. Ambler, PA: Lippincott Williams & Wilkins; 2005.

ORIGINAL POSTER PRESENTED AT*:

19th Annual Symposium on Advanced Wound Care (SAWC). Poster #315. April 30 – May 3, 2006. San Antonio, TX USA

21st Annual Clinical Symposium on Advances in Skin & Wound Care. Poster #56. September 28 – October 1, 2006. Orlando, FL USA

The WOCN Society's 39th Annual Conference. Poster #1240. June 10 - 13, 2007. Salt Lake City, UT USA

* This version has been modified from the original; it reflects PolyMem branding.

PolyMem, PolyMem Silver, PolyMem Wic, Wic, PolyMem Wic Silver, PolyMem Wic Silver Rope, PolyMem Max, Max, PolyMem Max Silver, Shapes, Shapes by PolyMem, The Shape of Healing, The Pink Dressing, SportsWrap, SportsWrapST, More Healing • Less Pain, interlocking circles design, PolyMem For Sports, Not too Loose...Not too Tight...Just Right!, Ferris and FMC Ferris and design are marks owned by or licensed to Ferris. The marks may be registered or pending in the US Patent and Trademark Office and in other countries. Other marks are the property of their respective owners.

© 2013 Ferris Mfg. Corp.

MKL-283,REV-4,0213