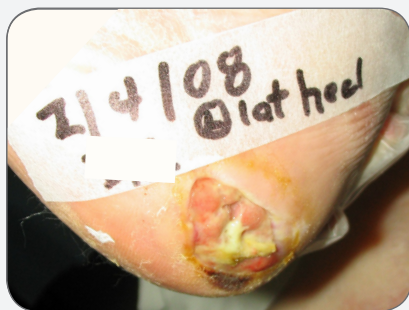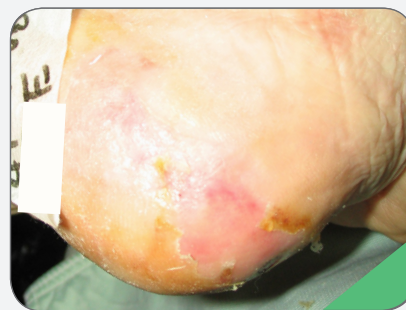


CASE STUDY

Heel Pressure Ulcer in Non-Compliant Patient Cleaned Up Quickly and Closed in Ten Weeks



SHAPES BY POLYMEM[®]
SILVER DRESSINGS WERE
INITIATED ON THIS STALLED
PRESSURE ULCER IN A
NON-COMPLIANT PATIENT



COMPLETE CLOSURE AFTER
10 WEEKS OF MANAGEMENT
WITH SHAPES BY POLYMEM
SILVER DRESSINGS AND DID
NOT RECUR, DESPITE
REFUSAL OF OFFLOADING

CASE STUDY

Heel Pressure Ulcer in Non-Compliant Patient Cleaned Up Quickly and Closed in Ten Weeks

DASIE WILSON, RNC, MPA, ET-CWCN, CCCN, Carlyle Nursing Associates LLC, 8140 River Drive, Morton Grove, IL 60053 USA

PROBLEM

A 90-year-old alert and oriented female with hypertension, morbid obesity, diabetes, arthritis, hypothyroidism, urinary incontinence and venous insufficiency treated with mild compression developed an unstageable left lateral heel pressure ulcer covered with stable black eschar, despite low air loss therapy. The stable black eschar was kept dry. Steroids were prescribed to prevent recurrence of bullous pemphigoid. Despite teaching the resident and her family, the patient frequently refused to allow staff to reposition her or float her heels.

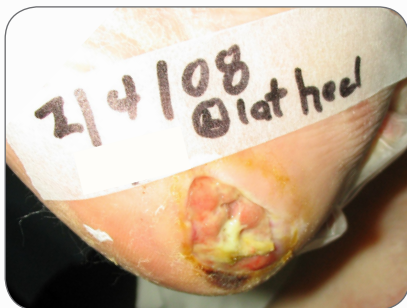The wound became malodorous with drainage and moderate erythema. Steroids to prevent recurrence of pemphigoid were increased due to new bullae formation. A hydrogel was used for 18 days to promote autolytic debridement of the heel wound eschar, which left the 2.0 cm x 3.0 cm x 0.5 cm deep approximately 60% clean pale pink tissue without granulation and 40% slough wound bed draining large amounts of yellow exudate with a reddened periwound. Antibiotics for cellulitis were initiated.

RATIONALE

Hydrogel dressings simply support autolytic debridement by maintaining a moist wound bed, but PolyMem dressings promote separation of slough from the wound bed, recruit fluid from the body to float the slough out of the wound and contain a super-absorbent to draw the fluid and slough into the dressing. Because PolyMem dressings have all of these features, they should provide superior wound cleansing and enhance the body's ability to autolytically debride wounds. PolyMem Silver® dressings do not leach cytotoxic small particle silver into the wound bed, so they are able to kill microbes without damaging fragile new growth in the wound bed, which should further speed healing.

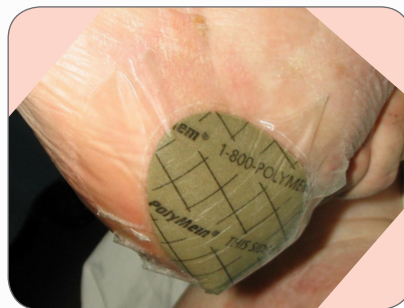
METHODOLOGY

The hydrogel dressings were replaced with Shapes by PolyMem Silver dressings with orders to check the dressing every shift and change it every-other-day and as needed. The dressing stayed in place remarkably well in light of the patient's refusal to off-load her foot.



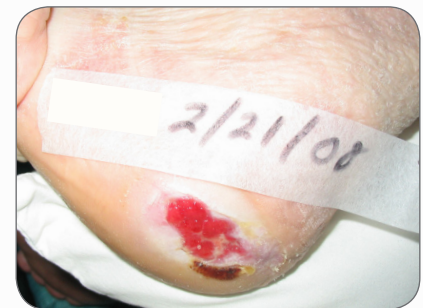FEB 4

2.0 cm x 3.0 cm x 0.5 cm unstageable pressure ulcer failed to improve with hydrogels, so Shapes by PolyMem Silver dressings were initiated. The 90-year-old patient refused to off-load her heels.



FEB 13

2.0 cm x 3.0 cm x 0.5 cm pressure ulcer staged as a III after it was completely cleaned by the synergistic action of the Shapes by PolyMem Silver dressings. Still refuses to allow heels to be floated.



FEB 21

2.0 cm x 3.0 cm x 0.2 cm Stage III pressure ulcer is filling in rapidly. Dressing changes, performed every other day, are quick and easy because no manual wound cleansing is needed.

RESULTS

Periwound redness resolved immediately. After less than two weeks the yellow slough was completely gone, leaving a 90% clean wound bed with 10% dry eschar at one edge draining only moderate amounts of pink serosanguineous drainage. The pressure ulcer was then classified as a Stage III. At one month of treatment with Shapes by PolyMem Silver dressings, the wound bed was only 1.0 cm x 2.5 cm x 0.2 cm with 20% epithelization, 80% granulation. The wound fully closed only ten weeks after initiation of treatment with Shapes by PolyMem Silver dressings.

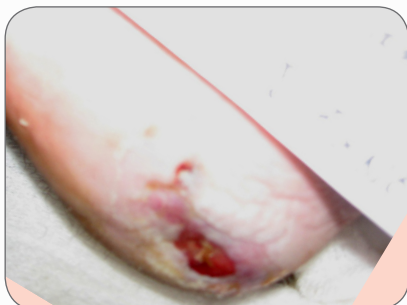
CONCLUSION

Shapes by PolyMem Silver dressings provided superior autolytic debridement and promoted healing while preventing infection in this extremely debilitated non-compliant patient to complete wound closure. These unique dressings do not leach cytotoxic small particle silver into the wound bed, so it was safe to provide this high risk patient with their antimicrobial benefits to complete wound closure.

OBJECTIVES

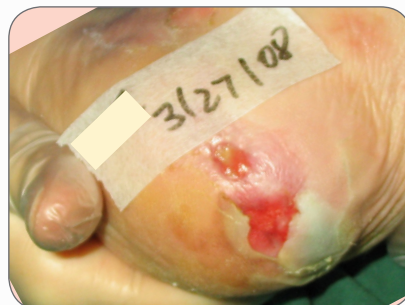1. Consider the advantages of using PolyMem dressings, which continuously cleanse the wound bed through a synergistic process which partners with the body's autolytic debridement, instead of using enzymes or hydrogels, which require manual wound bed cleansing at dressing changes.
2. Explore the evidence for the use of PolyMem Silver dressings to promote rapid wound healing while preventing infection.
3. Review the published independent research on the relative cytotoxicity of various silver dressings with respect to the use of PolyMem Silver dressings for periods of greater than two weeks.

This case study was unsponsored. Ferris Mfg. Corp. contributed to this poster presentation.



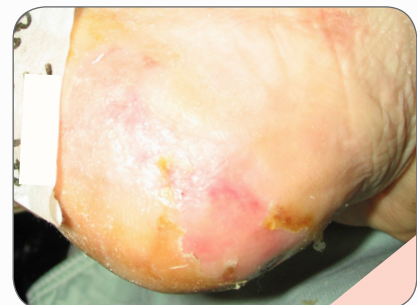MAR 14

1.0 cm x 2.5 cm Stage III pressure ulcer is fully granulated and 30% closed in only 38 days despite the patient's diabetes, venous insufficiency, steroid use and refusal to off-load the wound site.



MAR 27

0.5 cm x 1.9 cm Stage III pressure ulcer is exacerbated by recurrence of bullous pemphigoid. Steroid dose increased. PolyMem Silver dressings continue to clean wound and support healing.



APR 16

Wound was fully closed in only 10 weeks. Patient remained on steroids to prevent pemphigoid recurrence. Despite the patient's persistent refusal to offload, the wound did not recur.



Ferris Mfg. Corp.

5133 Northeast Parkway • Fort Worth, Texas 76106 USA

Toll Free USA: 1.800.POLYMEM (765.9636) • International: +1 817.900.1301

www.polymem.com

BIBLIOGRAPHY:

1. Enoch S, Harding K. Wound bed preparation: The science behind the removal of barriers to healing. *Wounds*. 2003;15(7):213-229.

2. Bergstrom N, Horn SD, Smout RJ, et al. The national pressure ulcer long-term care study: outcomes of pressure ulcer treatments in long-term care. *J Am Geriatr Soc*. 2005;53(10):1721-1729.

3. Yastrub DJ. Relationship between type of treatment and degree of wound healing among institutionalized geriatric patients with stage II pressure ulcers. *Care Manag J*. 2004 Winter;5(4):213-8.

4. Burd A, Kwok CH, Hung SC, Chan HS, Gu H, Lam WK, Huang L. A comparative study of the cytotoxicity of silver-based dressings in monolayer cell, tissue explant, and animal models. *Wound Repair and Regeneration* 2007;15:94-104.

5. Agathangelou C. Huge Sacral Pressure Ulcer Closed in Four Months Using PolyMem® Silver™ Dressings. Presented at 17th Conference of the European Wound Management Association (EWMA). Poster #135, May 2 – 4, 2007. Glasgow, Scotland.

6. Paddle-Ledinek, J. E., Z. Nasa, et al. Effect of different wound dressings on cell viability and proliferation. *Plast Reconstr Surg* 2006;117(7 Suppl): 1105-118S; discussion 119S-120S

ORIGINAL POSTER PRESENTED AT*:

23rd Annual Clinical Symposium on Advances in Skin & Wound Care. Poster #21. October 26 - 30, 2008. Las Vegas, NV USA.

NPUAP 11th Annual Biennial Conference. Poster #44. February 27 - March 1, 2009. Arlington, VA USA.

* This version has been modified from the original; it reflects PolyMem branding.

PolyMem, PolyMem Silver, PolyMem Wic, PolyMem Wic Silver, PolyMem Wic Silver Rope, PolyMem Max, Max, PolyMem Max Silver, Shapes, Shapes by PolyMem, The Shape of Healing, The Pink Dressing, SportsWrap, SportsWrapST, More Healing • Less Pain, interlocking circles design, PolyMem For Sports, Not too Loose...Not too Tight...Just Right!, Ferris and FMC Ferris and design are marks owned by or licensed to Ferris. The marks may be registered or pending in the US Patent and Trademark Office and in other countries. Other marks are the property of their respective owners.

© 2014 Ferris Mfg. Corp.

MKL-390,REV-2,0414